



Case report

Death by bleomycin pulmonary toxicity in ovarian dysgerminoma with pathologic complete response to chemotherapy. A case report



Julia Calzas Rodríguez^{a, *}, María del Carmen Juárez Morales^b,
Miguel Angel Racionero Casero^b

^a Department of Medical Oncology, University Hospital Fuenlabrada, Spain

^b Department of Pulmonology, University Hospital Fuenlabrada, Spain

ARTICLE INFO

Article history:

Received 24 November 2015

Received in revised form

14 April 2016

Accepted 15 April 2016

Keywords:

Ovarian dysgerminoma

Bleomycin

Pulmonary toxicity

Older patients

Pulmonary function test

ABSTRACT

With cisplatin-based chemotherapy, most patients with ovarian dysgerminoma will survive long-term. Bleomycin is an important part of ovarian germ cell tumors (OGCT) treatment, and its dose-limiting toxicity is the development of pulmonary toxicity and it is increased in patients older than 40 years. We report the case of an elderly patient with an unresectable ovarian dysgerminoma who received neoadjuvant chemotherapy and who developed fatal bleomycin pulmonary toxicity (BPT) after surgery. A monitoring of pulmonary function is not routinely recommended for detecting BPT, although together with carefully assessment for symptoms or signs suggestive of pulmonary toxicity is the best way to reduce the risk of BPT. The frequency of pulmonary events in older patients makes us to think about the possibility of either reduce the dose of bleomycin or removing it from the BEP in ovarian GCT.

© 2016 The Authors. Published by Elsevier Ltd. This is an open access article under the CC BY-NC-ND license (<http://creativecommons.org/licenses/by-nc-nd/4.0/>).

1. Introduction

Currently, ovarian dysgerminoma patients have an excellent prognosis if treated according to modern principles, consisting of chemotherapy with the BEP regimen (bleomycin, etoposide and cisplatin) combined with adequate surgery. However the major limitation of the therapy with bleomycin is the potential development of an interstitial pulmonary fibrosis life-threatening. We report the case of an elderly patient with an unresectable ovarian dysgerminoma, who achieved a pathologic complete response to the neoadjuvant chemotherapy and developed a severe and fatal pulmonary fibrosis.

2. Case report

A 62 years old woman non-smoker and without a medical history went to the emergency department with a strong pain in her left lumbar zone. On examination, she presented a positive

Blumberg sign. An abdominal computed tomography (CT) scan was performed and it showed a retroperitoneal tumor located near left kidney hilum (70 × 50 × 30 mm) with infiltration of renal vessels and psoas muscle (Fig. 1). There were a lot of regional pathologic lymph nodes and a left ovarian mass. The study was completed with chest CT, that it was normal. A biopsy with thick needle of the retroperitoneal tumor guided by ecography was performed. Histologic examination was consistent with dysgerminoma. The case was assessed by gynecologic oncologists who rejected surgery by unresectable bulky retroperitoneal tumor. She was sent to the oncology department with the diagnosis of ovarian dysgerminoma stage III (FIGO stage). Blood test showed high levels beta human chorionic gonadotropin (BHGC 20 UI/L (0-5)) and lactate dehydrogenase (LDH 350 U/L (80-220)). The pulmonary function test and diffusion capacity of carbon monoxide (DLCO) were normal. Our patient started neoadjuvant chemotherapy with BEP (Bleomycin, Etoposide, Cisplatin) every 21 days. After the first cycle the patient presented febrile neutropenia (it started colony stimulating factors, and it continued in the next cycles like secondary prophylaxis) and normalize the level of LDH y BHGC. After the third cycle, the CT scan showed a partial response in retroperitoneal mass (40 × 30 × 10 mm) and a complete response in the regional pathologic lymph nodes and left ovary tumor. But in the thorax, it revealed small ground-glass basal infiltrates in both lungs. A fourth cycle without bleomycin was administered. A week later, the

Abbreviations: OGCT, Ovarian germ cell tumors; BPT, bleomycin pulmonary toxicity; BEP, Bleomycin, Etoposide, Cisplatin; CT, computed tomography.

* Corresponding author. Department of Medical Oncology, University Hospital Fuenlabrada, Camino del Molino 2, 28942 Fuenlabrada, Madrid, Spain.

E-mail address: jcalzas.hflr@salud.madrid.org (J. Calzas Rodríguez).

<http://dx.doi.org/10.1016/j.rmcr.2016.04.004>

2213-0071/© 2016 The Authors. Published by Elsevier Ltd. This is an open access article under the CC BY-NC-ND license (<http://creativecommons.org/licenses/by-nc-nd/4.0/>).

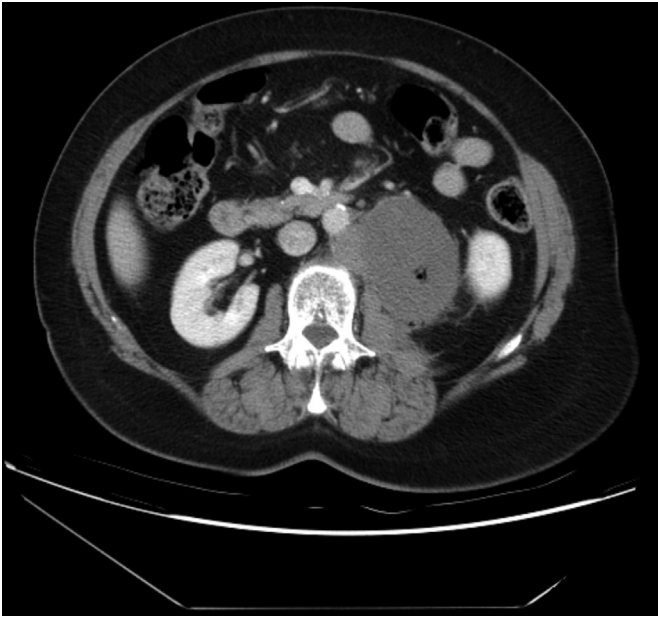

Fig. 1. Abdominal CT scan prior to treatment demonstrating a bulky retroperitoneal tumor.

patient needed admission to the hospital because of dyspnea with dry cough. She presented fine bibasilar crackles and hypoxemia. Prednisone dose to 1 mg/kg/day, oxygen therapy and broad-spectrum antibiotics was initiated. Pulmonary function tests showed a diffusion lung capacity of carbon monoxide (DLCO) markedly decreased to 30%. In the high-resolution chest tomography the findings were compatible with a diffuse interstitial pneumonitis (clear-worsening compared to previous CT scan) (Fig. 2). The bronchoscopy with alveolar washing was normal and without diagnosis in the transbronchial biopsy.

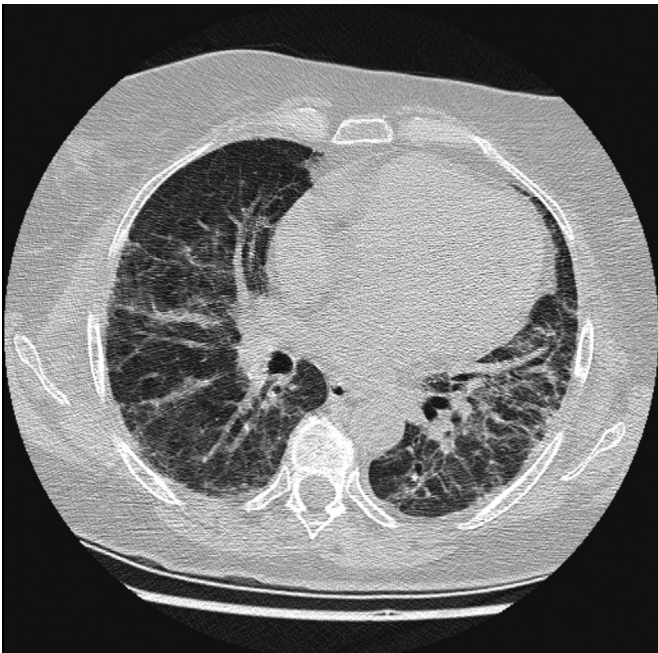


Fig. 2. High-resolution computed tomography of the chest showing diffuse interstitial pneumonitis.

In the following two months, the patient presented a progressive respiratory clinic improvement with gradually decreasing doses of corticoids, with improvement in the respiratory functional and radiology tests. At that time, abdominal CT scan shows a smaller and better delimited retroperitoneal tumor with a clear separation of the aorta and psoas muscle. Finally, after a preoperative assessment by anesthesia service, we decided interval debulking surgery with curative purpose. The retroperitoneal mass is removed hardly, but with optimal vascular and ureteral control. A hysterectomy with bilateral salpingo-oophorectomy were performed. After the operation, the patient began with acute dyspnea. Complementary tests showed a severe hypoxemic respiratory insufficiency and bilateral pulmonary infiltrates on chest radiograph. An acute respiratory distress syndrome was diagnosed. Intubation was required and connecting to invasive ventilation. The patient had to be in the intensive care unit during three weeks without possibility of extubation. Infection or inflammation were excluded. The respiratory deterioration was attributed to a progressive pulmonary fibrosis for bleomycin. Our patient finally died. Pathologic examination revealed no viable tumor cells.

3. Discussion

Although the dysgerminoma is the most common malignant germ cell tumor of the ovary, the OGCT are rare malignancies and account for only about 2–3% of all malignant ovarian neoplasms. The majority of cases (75%) are presented in adolescents and young adults. Seventy-five percent of women with dysgerminomas are presented with stage I disease. Due to its rarity, female GCT are difficult to study, and management is largely based on trials of male GCT and epithelial ovarian cancer. It consisted of primary surgical cytoreduction and after that, the chemotherapy. However, neoadjuvant chemotherapy followed by surgery is indicated for patients who are not surgical candidates at the time of diagnosis [2]. The 3–4 cycles BEP are recommended as the standard chemotherapy regimen for female GCT [1]. Germ cell tumors are a highly curable malignancy. In fact, with the modern cisplatin-based adjuvant chemotherapy (BEP), approximately 80% of patients who present with advanced disease will be long-term survivors, even if they have residual disease remaining after cytoreductive surgery. In this report we described a case of dysgerminoma with an uncommon clinical presentation: it arises in the 7th of life as a bulky metastatic unresectable disease requiring chemotherapy before surgery.

Unlike testicular cancer, clinical prognosticators of risk are less well defined for OGCT.

Age >40 at diagnosis, incomplete surgical resection, stage higher than 1, and yolk sac histology have been suggested as high-risk features [3,4]. The increased comorbidities, the reduced treatment intensity combined with the increased therapy-related toxicity might explain low survival in older women [5].

Bleomycin is an important part of GCT treatment but it is associated with lung injury, including 1–3% fatal bleomycin-induced pneumonitis [6]. The incidence bleomycin pulmonary toxicity (BPT) is largely dependent on cumulative drug dose. A total dose less than 300mg rarely causes BPT, whereas the risk increases when the cumulative dose exceeds 400mg. So in trials of standard-dose of chemotherapy for germ cell tumors (three or four cycles, which contain a cumulative bleomycin dose of 270 or 360 mg (units)), fatal pulmonary toxicity rates have been in the range of 0 to 1 and 0 to 3 percent, respectively. Other established risk factors for the development of BPT are a reduced renal function (a low glomerular function produces an increase the bleomycin half-life leading to longer exposure of the lungs), cigarette smoking, chest irradiation, prior lung disease and an older age [7]. The United

Kingdom Royal Marsden NHS Trust reported that 835 patients treated with bleomycin-containing regimen for germ cell tumors, with age over 40 was associated with a 2.3 fold higher risk of pulmonary complications [8]. Our patient received a total dose of bleomycin 270 mg(units), with a normal kidney function during all the process, without ureter obstruction by the huge para-aortic lymphadenectomy metastasis. In this case, the only risk factor for the development of pulmonary toxicity was the age of the patient. Among the perioperative risk factors of postoperative pulmonary complication by bleomycin have been described the duration of surgery, hyperoxia, volume and rate of fluid administration and red blood cell transfusion [9]. In a recent review of the patients who had received a bleomycin chemotherapy and subsequently underwent a major surgical procedure [10], the incidence of adult respiratory distress syndrome (ARDS) was only 1.3%.

No clinical study has assessed the efficacy of Etoposide-Platinum (EP) in ovarian GCT [11,12]. Based on data extrapolated from the testicular cancer literature, rather than from prospective trials in the malignant OGCT population, the use of EP can be considered in patients who cannot receive bleomycin. At the time of diagnosis, our patient had no absolute contraindications for bleomycin treatment.

There is a paucity of data with no clear consensus regarding the use of pulmonary function tests, particularly the carbon dioxide diffusion capacity (DLCO), as a screening for lung toxicity during therapy with a bleomycin-containing regimen. Some institutions recommend to do only baseline pulmonary function test and only it will be repeated if it is clinically indicated [1,13]. Other centers perform serial monitoring of DLCO, before to each cycle, with discontinuation of bleomycin when de DLCO decline >40% during treatment [14,15].

4. Conclusions

Nearly all patients with advanced dysgerminoma treated with chemotherapy are long term completed responders. However, minimizing toxicity is necessary. Except the tight monitorización of the kidney function in patients who received bleomycin, does not exist a clinically predictive test of significant bleomycin lung toxicity. Nevertheless, monitoring of the lung function (DLCO/FVC test) during treatment should be performed, mainly in patients aged ≥ 40 years. In addition, avoiding or early stopping bleomycin

in ovarian GCTs ovarian GCTs should be investigated, without compromise the outcome.

Competing interests

None declared.

References

- [1] National Comprehensive Cancer Network (NCCN), NCCN Clinical Practice Guidelines in Ovarian Cancer. Version 2, 2015. http://www.nccn.org/professionals/physician_gls/pdf/ovarian.pdf (accessed 31.01.16).
- [2] S. Talukdar, S. Kumar, N. Bhatla, et al., Neo-adjuvant chemotherapy in the treatment of advanced malignant germ cell tumors of ovary, *Gynecol. Oncol.* 132 (2014) 28–32.
- [3] C. Mangili, C. Sigismondi, A. Gadducci, P. Cormio, et al., Outcome and risk factors for recurrence in malignant ovarian germ cell tumors: a MITO-9 retrospective study, *Int. J. Gynecol. Cancer* 21 (2011) 1414–1421.
- [4] O. Solheim, D.M. Gershenson, C.G. Tropé, et al., Prognostic factors in malignant ovarian germ cell tumours (The surveillance, epidemiology and end results experience 1978–2010), *Eur. J. Cancer* 50 (11) (2014 Jul) 1942–1950.
- [5] F.B. Thomsen, M. Bandak, M.F. Thomsen, et al., Survival and toxicity in patients with disseminated germ cell cancer aged 40 years and older, *Cancer* 1 (2014) 43–51.
- [6] S. Sleijfer, Bleomycin-induced pneumonitis, *Chest* 120 (2) (2001) 617–624.
- [7] M. Froudarakis, E. Hatzimichael, L. Kyriazopoulou, et al., Revisiting bleomycin from pathophysiology to safe clinical use, *Crit. Rev. Oncol. Hematol.* 87 (1) (2013) 90–100.
- [8] J.M. O'Sullivan, R.A. Huddart, A.R. Norman, et al., Predicting the risk of bleomycin lung toxicity in patients with germ-cell tumours, *Ann. Oncol.* 14 (2003) 91–96.
- [9] S.M. Donat, D.A. Levy, Bleomycin associated pulmonary toxicity: is perioperative oxygen restriction necessary? *J. Urol.* 160 (4) (1998) 1347–1352.
- [10] B.M. Aakre, R.I. Efem, G.A. Wilson, et al., Postoperative acute respiratory distress syndrome in patients with previous exposure to bleomycin, *Mayo Clin. Proc.* 89 (2014) 181–189.
- [11] C.G. Simone, M.J. Markham, D.S. Dizon, Chemotherapy in ovarian germ cell tumors: a systematic review, *Gynecol. Oncol.* (2016), <http://dx.doi.org/10.1016/j.ygyno.2016.02.007>.
- [12] A.R. Abdul Razak, A. Li, M. Bryant, et al., Chemotherapy for malignant germ cell ovarian cancer in adult patients with early stage, advanced and recurrent disease, *Cochrane Database Syst. Rev.* 16 (3) (2011 Mar) CD007584, <http://dx.doi.org/10.1002/14651858>.
- [13] H.S. Haugnes, J. Oldenburg, R.M. Bremnes, Pulmonary and cardiovascular toxicity in long-term testicular cancer survivors, *Urol. Oncol.* 33 (9) (2015) 379–420.
- [14] B.M. Shippee, J.S. Bates, K.L. Richards, The role of screening and monitoring for bleomycin pulmonary toxicity, *J. Oncol. Pharm. Pract.* 22 (2) (2016 Apr) 308–312 pii: 1078155215574294 [Epub ahead of print].
- [15] N. Delanoy, N. Pecuchet, E. Fabre, et al., Bleomycin-induced pneumonitis in the treatment of ovarian sex cord-stromal tumors: a systematic review and meta-analysis, *Int. J. Gynecol. Obstet.* 25 (9) (2015) 1593–1598.