

Case Report

Herpetic ocular manifestations in a patient with GATA2 deficiency



Ana I. Ortueta-Olartecoechea; José L. Torres-Peña*; Ana I. Palacios-Hípola; Enrique Mencia-Gutierrez

Abstract

Specific genetic deficiencies are a rare cause that should be included in the diagnostic algorithm of disseminated herpetic lesions. The aim of this article is to describe the ocular herpetic manifestations in a rare genetic disorder called GATA2 deficiency. We present the clinical case of a 26-year-old male with dendritic ulcers in his cornea, marrow aplasia and idiopathic chronic lymphedema. He was diagnosed with GATA2 deficiency. GATA2 gene is critical for the genesis and function of hematopoietic stem cells. Its deficiency can cause myelodysplastic syndromes, congenital lymphedema and severe viral infections. Our patient presented these three manifestations, added to a deletion in 20q12 that confirmed the suspicion of GATA2 mutation. A bone marrow transplant was suggested as definitive treatment. The corneal herpetic epithelial lesion was analogous to a regular herpetic keratitis with none stromal keratitis.

Keywords: GATA2 deficiency, Herpetic keratitis, HIV, Myelodysplastic syndrome, 20q12 deletion, Foscarnet, Herpetic disseminated infection

© 2017 The Authors. Production and hosting by Elsevier B.V. on behalf of Saudi Ophthalmological Society, King Saud University. This is an open access article under the CC BY-NC-ND license (<http://creativecommons.org/licenses/by-nc-nd/4.0/>). <https://doi.org/10.1016/j.sjopt.2017.11.001>

Introduction

Cutaneous and ocular disseminated herpetic lesions have many causes, such as human immunodeficiency virus (HIV) infection, chemotherapy treatment or primary immunodeficiency. Specific genetic deficiencies are an unusual cause that should be included in the diagnostic algorithm. The lack of an effective cell mediated immune response in immunocompromised patients may result in a huge viral load, may be implicated in a prolonged course of cutaneous infection and resistance to antiviral treatment.^{1,2}

We present a clinical case of a young man with periocular, ocular and systemic herpetic lesions, due to a deficiency in GATA2 gene. This is a human gene encoding a protein called GATA binding protein 2, which is a transcription factor that

regulates hematopoietic stem cell homeostasis. There are few cases that can be found in literature.

Case report

A 26-year-old male came to our clinics, referred with red eye, pain and superior eyelid swelling in his left eye for 1 week. He had previously been diagnosed with cellulitis because of cutaneous erythematous lesions in his left leg and he had been treated with oral amoxicillin.

In his medical background, a diagnosis of bone marrow aplasia from four years ago was found. It had been treated with danazol; in addition, there was an idiopathic chronic lymphedema diagnosis from 13 years ago.

Received 16 October 2016; received in revised form 4 November 2017; accepted 5 November 2017; available online 13 November 2017.

12 de Octubre University Hospital, Ophthalmology Department, Complutense University, Madrid, Spain

* Corresponding author.

e-mail address: jos_luit@hotmail.com (J.L. Torres-Peña).



Peer review under responsibility of Saudi Ophthalmological Society, King Saud University



Production and hosting by Elsevier

Access this article online: www.saudiophthaljournal.com www.sciencedirect.com

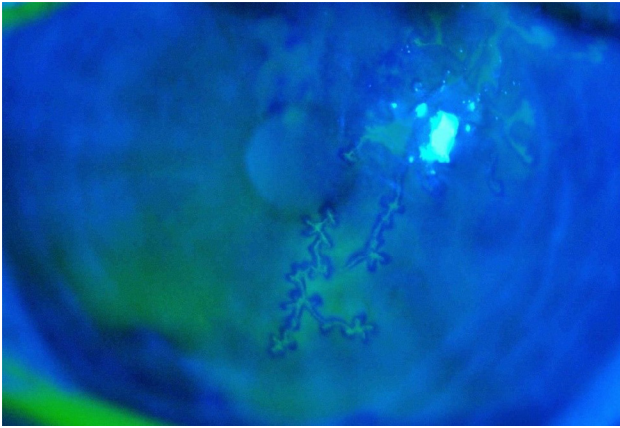


Fig. 1. Herpes keratitis in his left eye.

In the ophthalmological examination, he presented with upper left eyelid edema and reactive conjunctival chemosis; the cornea was clear. He was treated for an external hordeolum with hydrocortisone-oxytetracycline-polymyxin B ointment. Two days later he developed two paracentral dendritic ulcers that stained with fluorescein but with no underlying stromal involvement in his left cornea (Fig. 1), and the upper eyelid edema persisted. At that point his best corrected visual acuity (BCVA) on the decimal scale was 0.3, which improved to 0.5 with pinhole in his right eye and 0.5 without improvement with pinhole in his left eye. Intraocular pressure was 15 mmHg in both eyes. The hydrocortisone-oxytetracycline-polymyxin B ointment was suspended and treatment with acyclovir ointment 5 times a day and a topical lubrication ointment 3 times a day was then started.

At the same time, he presented herpetic lesions in his left leg, fever and massive aphthous-like ulcerations in oral mucosa with pseudomembranes (Fig. 2). His blood tests detected leukopenia 800 cel/ μ l (4000–11,300), neutropenia and prothrombin activity of 43% (75–140). Also the ALT 2 963 UI (5–45) and the AST 2 667 UI (5–37) were elevated, as the PCR was 33.2 mg/dl (0.10–0.50).

The treatment with amoxicillin was suspended as no improvement of the cutaneous lesions was detected and treatment with meropenem, acyclovir and nystatin was started, as a prophylaxis for his leukopenia. Several serology tests for cytomegalovirus, Epstein-Barr virus, herpes zoster, herpes simplex, syphilis and hepatitis A, B and C were performed, all of them with negative results. The skin and oral

lesions biopsy were positive for herpes simplex virus type 2 (HSV-2). The corneal dendritic ulcer persisted despite topical acyclovir. A bone marrow biopsy was informed for myelodysplastic syndrome with multilineage dysplasia, and a severe decrease in the Natural Killer (NK) cell activity, monocytopenia, and a B leukocyte deficit. For these reasons, it was suspected that the patient carried a GATA2 deficiency; this was confirmed by a deletion in 20q12. Tests for deletions 5q31 and 7q31 were negative.

The skin lesions continued despite systemic acyclovir treatment. Three weeks later, the treatment was changed to systemic foscarnet, with good clinical response in the skin and oral lesions. After the resolution of the dendritic ulcers, the BCVA in his left eye was 0.7.

A bone marrow transplant was suggested, but the patient refused, as he wanted to be followed up in his country of origin.

Discussion

Systemic herpetic lesions are associated with primary or secondary immunodeficiency syndromes, with the secondary being more frequent. Previous studies have documented a high prevalence of HSV-1 and HSV-2 in HIV-infected homosexual men and have shown that HSV manifestations may become chronic in such patients.³ Regarding primary causes, gene deficiency is rare, and needs high level of suspicion to be recognized. Our patient presented a deficiency in GATA2 gene, which was detected after a complete systemic study.

The GATA gene belongs to a family of zinc finger transcription factors that regulates stem cell homeostasis.⁴ There are 3 types of GATA. GATA1 works primarily in erythropoiesis and megakaryopoiesis and GATA3 in T-cell lymphopoiesis. GATA2 is particularly critical for hematopoietic stem and progenitor cells genesis and function and, thus, all subsequent blood cell lineages.

The clinical hallmarks of GATA2 deficiency include infections with human papillomaviruses (HPV) and nontuberculous mycobacteria (NTM), predisposition to myelodysplastic syndromes (MDS) or acute myeloid leukemia (AML), pulmonary alveolar proteinosis (PAP), and congenital lymphedema.⁵

Initial clinical presentations are variable: severe viral infections, disseminated NTM infections, MDS/AML, lymphedema, and invasive fungal infections. From those, our patient presented a severe HSV infection, MDS and lymphedema.

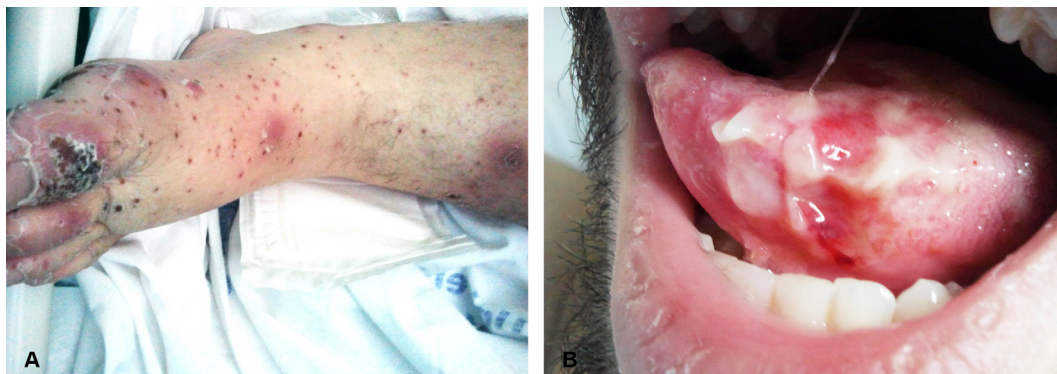

Fig. 2. Herpetic lesions in his left leg (A); and massive aphthous-like ulcerations in oral mucosa with pseudomembranes (B).

Severe viral infections are the most common presentation, particularly with HPV and herpesvirus reactivations that include keratitis, herpes stomatitis, esophagitis or genital lesions and varicella.

This susceptibility may be attributed to deficiency and/or dysfunction of NK cells, which are critical for antiviral immunity.⁶

In patients with primary immunodeficiency, we have to consider an increased treatment resistance.⁷ That is what happened to our patient, who had a poor response to acyclovir but a good one to foscarnet.

The ophthalmological management of these patients is similar to those with no immunodeficiency. Our patient received treatment with acyclovir ointment and a topical lubrication ointment with a good outcome. The corneal epithelial lesion is not different from other herpetic keratitis; which is attributed to the cytopathic effect of the virus. Furthermore, the vision impairment in stromal keratitis is believed to represent an immunopathological response to virus. Stromal disease appears, at least in part, to be an immunological lymphocyte response to HSV antigens in the cornea. It is thus conceivable that the lymphocyte dysfunction associated with immunosuppression by immunodeficiencies might have actually protected this patient against developing stromal keratitis.⁷

Congenital immune deficiencies are rare; that is why both a high degree of suspicion and the work of a multidisciplinary team are required to reach a clinical diagnosis which later becomes a genetic one. In this case the herpetic keratitis

was an early manifestation of the systemic viral infection, which had a good response to a second line treatment with foscarnet.

Conflict of interest

The authors declared that there is no conflict of interest.

References

1. Hoppenjans WB, Bibler MR, Orme RL, Solinger AM. Prolonged cutaneous herpes zoster in acquired immunodeficiency syndrome. *Arch Dermatol* 1990;**126**:1048–50.
2. Dilley D, Chandler RG, Gupta A. Resistant herpes infection of the palm in a patient with acquired immunodeficiency syndrome: a case report. *J Hand Surg Am* 1997;**22**:650–2.
3. Safrin S, Ashley R, Houlihan C, Cusick PS, Mills J. Clinical and serologic features of herpes simplex virus infection in patients with AIDS. *AIDS* 1991;**5**:1107–10.
4. Chou J, Lutskiy M, Tsitsikov E, Notarangelo LD, Geha RS, Dioun A. Presence of hypogammaglobulinemia and abnormal antibody responses in GATA 2 deficiency. *J Allergy Clin Immunol* 2014;**134**:223–6.
5. Dickinson RE, Milne P, Jardine L, Zandi S, Swierczek SI, McGovern N, et al. The evolution of cellular deficiency in GATA 2 mutation. *Blood* 2014;**123**:863–74.
6. Spinner MA, Sanchez LA, Hsu AP, Shaw PA, Zerbe CS, Calvo KR, et al. GATA 2 deficiency: a protean disorder of hematopoiesis, lymphatics and immunity. *Blood* 2014;**123**:809–21.
7. Pramod NP, Hari R, Sudhamathi K, Ananadakannan K, Thyagarajan SP. Influence of human immunodeficiency virus status on the clinical history of herpes simplex keratitis. *Ophthalmologica* 2000;**214**:337–40.